

# Giant Traumatic Cervical Pseudomeningocele After Brachial Plexus Injury: A Report of 2 Cases

*Antônio J. Tedesco-Marchese, MD, PhD,\* Edson Bor-Seng-Shu, MD, PhD,\*  
Arthur W. Poetscher, MD, PhD,\* Manoel J. Teixeira, MD, PhD,\* Pedro A. Arlant, MD, PhD,†  
Antônio S. de Araújo, Jr, MD,‡ and Mirella M. Fazzito, MD,‡*

**Abstract:** It is well known that a traction injury of the brachial plexus may produce tears in the root sleeves resulting in pseudomeningoceles, which are in most instances small and not noticed by the patient. We report 2 unusual cases of giant pseudomeningoceles due to brachial plexus injury presenting as a supraclavicular mass. Compression because of the mass resulted in headache, nausea, and dizziness in both cases. A computed tomography of the brain must be performed to rule out further causes of increased intracranial pressure. Ventriculoperitoneal and lumbar-peritoneal shunting procedures were the treatment of choice.

**Key Words:** giant pseudomeningocele, brachial plexus injury, ventriculoperitoneal shunts

(*Neurosurg Q* 2013;23:206–209)

The first description of traumatic meningocele or pseudomeningocele due to brachial plexus traction injuries was introduced by Murphey et al in 1947,<sup>1</sup> and since then its presence has been considered to be a typical sign of cervical nerve root avulsion, although there are studies showing pseudomeningoceles without nerve root avulsion.<sup>2–4</sup>

The mechanism of development of these pseudomeningoceles is a rupture of the meningeal cuff of a nerve root because of excessive traction force exerted on the brachial plexus resulting in the leakage of cerebrospinal fluid (CSF) into the surrounding extraspinal tissues.<sup>5–8</sup>

In the majority of the cases, pseudomeningoceles are small and remain asymptomatic only indicating a poor prognosis in relation to the recovery of the brachial plexus function at the corresponding level.<sup>4–8</sup> These explain the paucity of the treatment proposals in the literature for these cases. However, when the pseudomeningoceles are giants, they may produce symptoms of increased intracranial

pressure when compressed and an unaesthetic bulge in the supraclavicular region, or even symptoms of respiratory failure because of pleural effusion,<sup>2</sup> making the treatment necessary. To our knowledge, only 4 cases are available in the literature concerning giant pseudomeningoceles after brachial plexus injury.<sup>2,4,9</sup>

The purpose of the present manuscript is to report 2 cases of symptomatic giant cervical pseudomeningocele due to a traction injury in the brachial plexus. In both cases, there was a large bulging in the left supraclavicular region, and the treatment of choice was a CSF diversion procedure (ventriculoperitoneal and lumboperitoneal shunts).

## CASE REPORT

### Case 1

A 32-year-old man was injured in a motorcycle accident and was admitted to another hospital. He sustained a head injury and a complete lesion of the left brachial plexus. One month after trauma, the patient was admitted to another hospital for brachial plexus injury repair. Three months later, he developed hydrocephalus and underwent placement of a ventriculoperitoneal shunt.

Two months after surgery, he noted a progressive bulging in the left supraclavicular region and experienced headache, nausea, and dizziness when the bulging was compressed. He was then brought to our hospital and was found to have a large bulging in the left supraclavicular region, which was of cystic consistency, painless, and without pulsation or murmurs (Fig. 1A). He also presented a marked hypotrophy with complete paralysis and numbness of the left upper limb and Horner syndrome on the left side. Pumping the shunt valve suggested shunt malfunction.

Cervical magnetic resonance imaging (MRI) revealed a large collection of CSF intensity on both T1-weighted and T2-weighted images, lateral to the cervical spine, in the left supraclavicular and cervical region, compatible with pseudomeningocele (Figs. 1B–D).

Cisternography with DTPA (<sup>99m</sup>Tc) by lumbar puncture demonstrated an abnormal concentration of isotope in the left supraclavicular region and a defect in CSF absorption (Fig. 1E).

Computed tomography (CT) of the brain disclosed a large dilatation of the ventricles and signs of increased intracranial pressure.

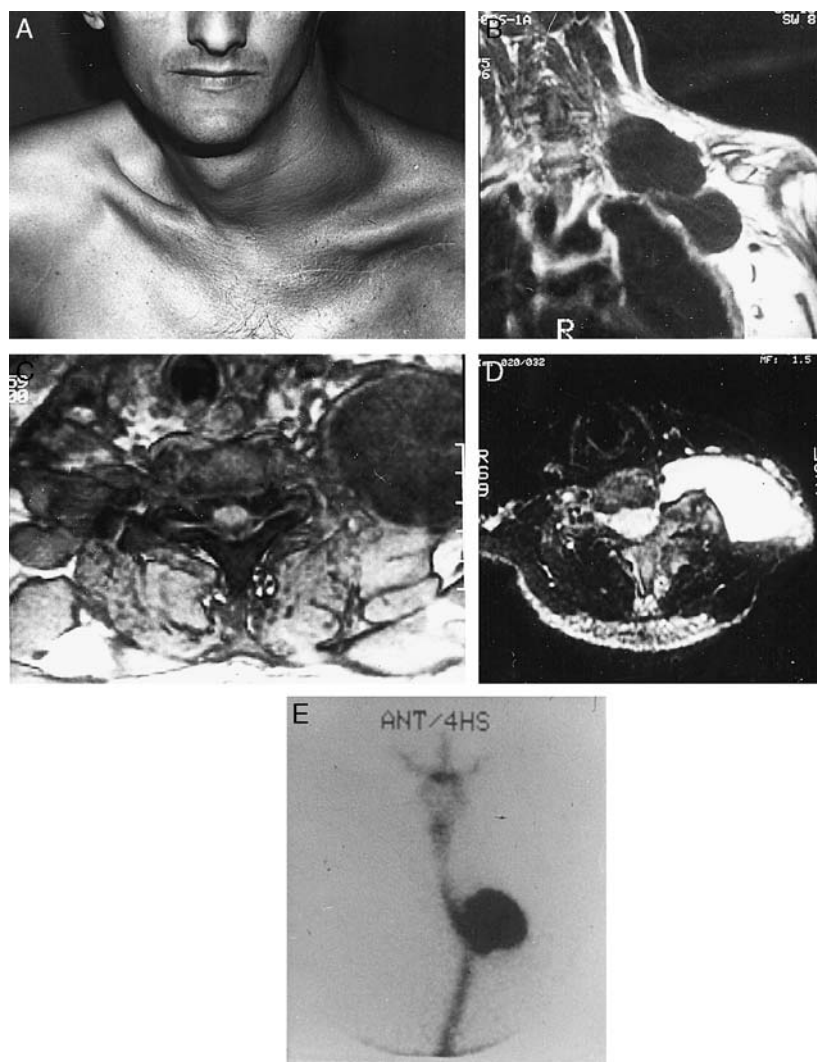
A lumbar puncture was performed and the CSF pressure was measured under 3 different conditions: under normal conditions, on abduction of the left upper limb, and on compression of the bulging. The CSF pressure was also measured using the same method after CSF withdrawal. After the CSF withdrawal,

From the \*Department of Neurosurgery, São Paulo University Medical School; Departments of †Neurosurgery; and ‡Neurology, Sirio-Libanês Hospital, São Paulo, Brazil.

The authors declare no conflict of interest.

Reprints: Antônio S. de Araújo, Jr, MD, Rua Peixoto Gomide, 515, cj 96, Cerqueira César, São Paulo, SP, Brazil CEP 01409-001 (e-mail: dr.antonioaraujojr@gmail.com).

Copyright © 2013 by Lippincott Williams & Wilkins



**FIGURE 1.** Cervical pseudomeningocele after brachial plexus injury. A, Left supraclavicular bulging; T1-weighted coronal MRI, cervicothoracic large collection of CSF intensity (B); T1-weighted axial MRI, left paravertebral CSF collection (C); T2 axial MRI, huge left paravertebral pseudomeningocele (D); cisternography with DTPA, left supraclavicular concentration of isotope (E), proving the diagnosis of pseudomeningocele. CSF indicates cerebrospinal fluid; MRI, magnetic resonance imaging.

the bulging was much smaller; however, it enlarged progressively afterward.

This patient was treated by changing the ventriculoperitoneal shunt system, with progressive disappearance of the bulging (Fig. 2).

## Case 2

A 25-year-old man was injured in a forceful traction to the left upper limb during an accident with a textile machine. Immediately afterward, he noticed complete paralysis and numbness of the upper limb and was admitted to another hospital with a hematoma in the left supraclavicular region, which was explored surgically. No active hemorrhage or vascular ruptures were identified. He was referred to our hospital 4 months later, complaining of a large unaesthetic bulging in the left supraclavicular region and a mild headache with nausea and dizziness when the large bulging was compressed. Further, he could not turn his head to the left adequately because of the bulging.

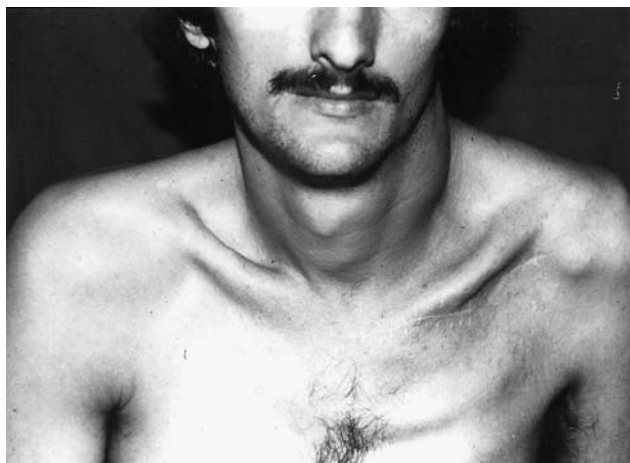
Physical examination at that time revealed a large painless bulging in the left supraclavicular region, of cystic consistency, without pulsation or murmurs (Fig. 3A), and a marked hypotrophy with complete paralysis and numbness of the upper limb. Horner syndrome was present on the left side.

Cervical MRI revealed focal collection of CSF intensity on both T1-weighted and T2-weighted images, measuring  $6.5 \times 6.5 \times 5.5$  cm, lateral to the cervical spine, in the left supraclavicular and cervical region suggestive of a pseudomeningocele (Fig. 3B).

Cisternography with DTPA ( $^{99m}\text{Tc}$ ) through lumbar puncture demonstrated an abnormal concentration of isotope in the left supraclavicular region. Defects in CSF absorption and circulation were not detected.

CT of the brain did not reveal signs of intracranial lesions or hydrocephalus.

A lumbar puncture was made and CSF pressure was measured under different conditions as performed in case 1.



**FIGURE 2.** Disappearance of the supraclavicular bulging after CSF shunting. CSF indicates cerebrospinal fluid.

After CSF withdrawal, the supraclavicular bulging reduced in size; however, it gradually enlarged in size again.

A lumboperitoneal shunting was then performed with the disappearance of the supraclavicular bulging.

## DISCUSSION

In most instances, pseudomeningoceles due to traction injury in the brachial plexus are small and not noticed by the patient. They usually occur as multiple lesions from C3 or C4 to T1 or T2, varying in size from a few mm to about 2 or 3 cm in length and about 1 or 2 cm in breadth.<sup>2,7</sup> One which measured 2 × 4 cm was regarded as a very large pseudomeningocele.<sup>7</sup> In contrast, giant pseudomeningoceles are considered extremely rare. We were able to find only 4 reports of giant pseudomeningoceles, resulting in supraclavicular bulging, after brachial plexus injuries.<sup>2,4</sup>

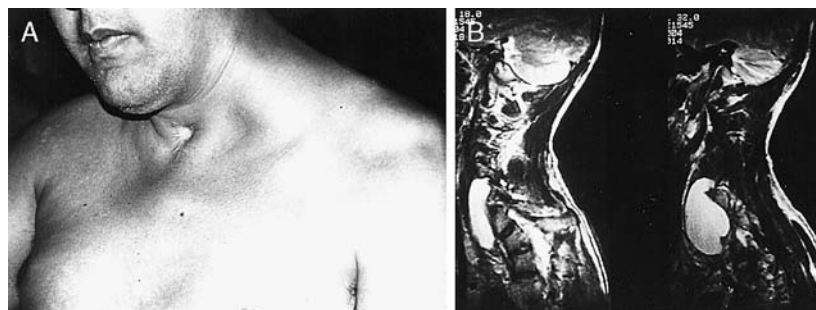
The differential diagnosis of supraclavicular bulging secondary to brachial plexus injury should always include a vascular rupture (subclavian artery pseudoaneurysm) and CSF effusion (pseudomeningocele), which may be distinguished with the help of neuroradiologic investigations,<sup>10</sup> such as CT myelography,<sup>3</sup> myelography,<sup>5</sup> or MRI.<sup>6</sup>

In 1972, Gass et al<sup>2</sup> reported the first 2 cases of giant pseudomeningoceles. One of them presented with a supraclavicular bulging and developed an incisional CSF fistula after vascular exploration of the supraclavicular region. This postoperative fistula disappeared after myelography. The other case presented dyspnea and a supraclavicular bulging. Investigation showed a large supraclavicular pseudomeningocele and CSF pleural effusion in the left hemithorax. This patient underwent a laminectomy and the duramater was sutured at the level of the tearing. The possibility of CSF pleural effusion due to brachial plexus traction injuries had already been demonstrated in 1971 by Epstein and Epstein,<sup>7</sup> who showed a case of extrapleural intrathoracic apical traumatic pseudomeningocele due to brachial plexus avulsion in an 18-year-old boy.

In 1983, Jakobsen et al<sup>4</sup> reported a case of a giant pseudomeningocele in the supraclavicular region, which measured 7 × 13 cm. This patient had a slight headache when the supraclavicular mass was compressed; however, he refused further treatment.

In 2008, Tanaka et al<sup>9</sup> reviewed 2 cases and reported 1 more case of a traumatic cervicothoracic pseudomeningocele after a brachial plexus avulsion injury, with an extremely rare transdural herniation of the spinal cord into it. The patient underwent primary closure of the pseudomeningocele to prevent spinal cord reherniation.<sup>9</sup> Transdural herniation of the spinal cord may be a risky complication of the traumatic pseudomeningocele.

With regard to the mechanism of pseudomeningocele formation, it is well known that the traction injury to the brachial plexus might produce tears in the root sleeves with formation of pseudomeningoceles. The latter become enlarged because of a continuous increased CSF pressure resulting in increased flow of CSF to extraspinal tissues, as demonstrated in case 1, which presented hydrocephalus. Therefore, it is very important to investigate these patients in relation to the causes of increased CSF pressure. The other possibility is that the pseudomeningocele and the CSF system constitute a 1-way valve system at the level of the dural tears so that the CSF could pass only from intradural to extraspinal tissues, the inverse not being possible under normal conditions. Therefore, during the physiological increase in CSF



**FIGURE 3.** Cervical pseudomeningocele. A, Left supraclavicular bulging and T2-weighted sagittal MRI, cervicothoracic collection of CSF intensity (B), suggesting a pseudomeningocele. CSF indicates cerebrospinal fluid; MRI, magnetic resonance imaging.

pressure as in the Valsalva maneuver caused by straining, coughing, or nose blowing, the CSF could leak into extraspinal tissues. This could be the explanation for those cases without clear evidence of pathologic increase in CSF pressure. In the management of our cases, cerebrospinal shunting was found to be a more reasonable procedure.

In both cases, immediately after compression of the mass, CSF pressure increased to 100 mm H<sub>2</sub>O. At this moment, both patients complained of headache, nausea, and dizziness. During the compression of the bulge, after a few seconds, case 2 presented a brief loss of consciousness. Abduction of the left upper limb also resulted in an increase in CSF pressure. When the compression of the bulging or abduction of the limb was interrupted, CSF pressure was rapidly lowered to basal levels.

In order to measure CSF pressure, a lumbar puncture with manometry was accomplished in both patients.

### CONCLUSIONS

The possibility of a giant pseudomeningocele presenting as a supraclavicular mass in a patient with a previous brachial plexus injury must be considered. CT scanning of the brain must be carried out to rule out the causes of increased intracranial pressure, such as hydrocephalus. When symptomatic, treatment of a giant pseudomeningocele may be necessary. In our cases, ventriculoperitoneal and lumboperitoneal shunting pro-

cedures were performed and shown to be effective treatment modalities.

### REFERENCES

1. Murphey F, Hartung W, Kirklin JW. Myelographic demonstration of avulsing injury of the brachial plexus. *Am J Roentgenol.* 1947;58:102–105.
2. Gass MMHH, Devadiga KV, Taptas JN. [Supraclavicular cerebrospinal liquid fistula after avulsion of the brachial plexus] Épanchement de liquid céphalorachidien sus-claviculaire après arrachement du plexus brachial. *Neurochirurgie.* 1972;18:541–542.
3. Hashimoto T, Mitomo M, Hirabuki N, et al. Nerve root avulsion of birth palsy: comparison of myelography with CT myelography and somatosensory evoked potential. *Radiology.* 1991;178:841–845.
4. Jakobsen H, Roder OC, Bojsen-Moller J. Large paracervical meningocele due to lesion of cervical spinal nerve roots. *Acta Chir Scand.* 1983;149:537–539.
5. Kewalramani LS, Taylor RG. Brachial plexus root avulsion: role of myelography. *J Trauma.* 1975;15:603–608.
6. Miller SF, Glasier CM, Griebel ML, et al. Brachial plexopathy in infants after traumatic delivery: evaluation with MR imaging. *Radiology.* 1993;189:481–484.
7. Epstein BS, Epstein JA. Extrapleural intrathoracic apical traumatic pseudomeningocele. *Am J Roentgenol.* 1974;120:887–892.
8. Rorabeck CH, Harris WR. Factors affecting the prognosis of brachial plexus injuries. *J Bone Joint Surg.* 1981;63:404–407.
9. Tanaka M, Ikuma H, Nakanishi K, et al. Spinal cord herniation into pseudomeningocele after traumatic nerve root avulsion: case report and review of the literature. *Eur Spine J.* 2008;17(suppl 2):S263–S266.
10. Vielvoye GJ, Hoffmann CFE. Neuroradiological investigations in cervical root avulsion. *Clin Neurol Neurosurg.* 1993;95(suppl):S36–S38.