

JAPAN NEUROSURGERY TECHNOLOGY

Hiroshima University

Japan

July 2014

Autologous bone marrow-derived mesenchymal stem cells transplantation in the treatment of chronic spinal cord injury

Antonio Santos de Araújo Júnior
Sírio-Libanês Hospital – São Paulo – Brasil

Our Team

- Celso Massumoto – Haematologist
- Sally Massumoto – Geneticist
- Lizier – Biologist
- Ayoub – Mollecular Biologist
- Rogerio Tuma e Mirella Fazzito – Neurologists
- Ricardo Ferreira – Electrophysiologist
- Marcos Docema – Neuroradiologist
- Jose Guilherme Caldas – Neurointerventional Radiologist
- Arnaldo Salvestrini e Pedro Arlant – Neurosurgeons

We declare no conflict of interest

"Recent advancements in developmental biology have brought stem cells into the forefront of scientific, political, and ethical discussions."

"Most clinicians have an intuitive sense of what stem cells are, but the significance of stem cell biology for their practice may not be fully appreciated."

Cheshier SH, Kalani MY, Lim M, Ailles L, Huhn SL, Weissman IL. **A neurosurgeon's guide to stem cells, cancer stem cells, and brain tumor stem cells.** Neurosurgery. 2009 Aug;65(2):237-49.

History

1665 – Robert Hooke – Cellular structure

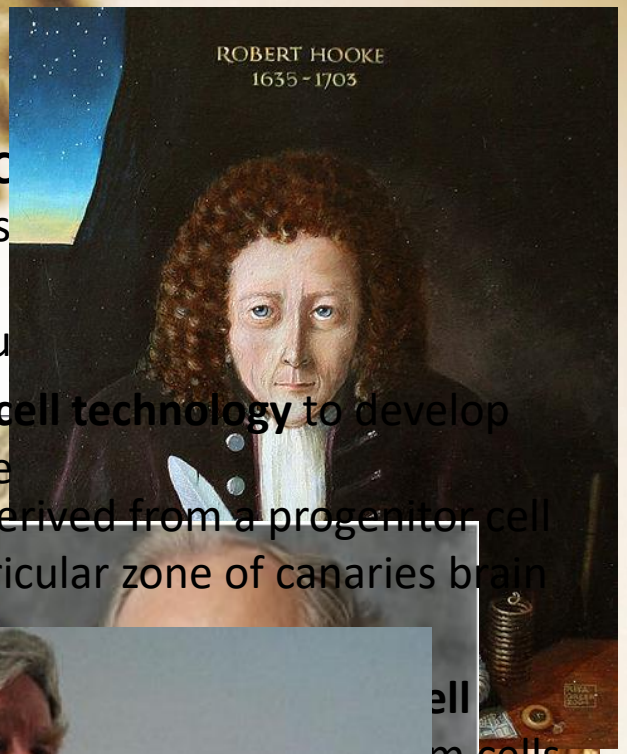

1961 – Till and McC
Transplantation of s
cells into irradiated
colonies in the mou

1977 – Mario Capecchi – Embryonic stem cell technology to develop
"knock-out" mice

1983 – Fernando Nottebohm - Neuronal growth derived from a progenitor cell
population in the subventricular zone of canaries brain

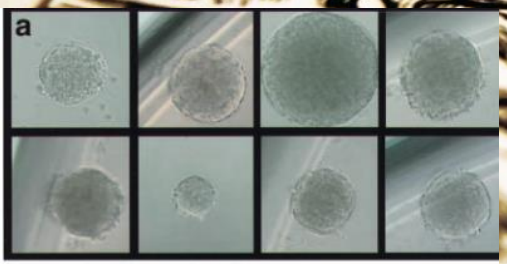

1988 - Gerald Span **ell**
sorting to isolate pu m cells

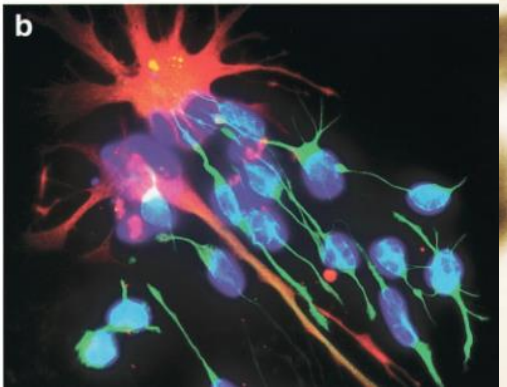

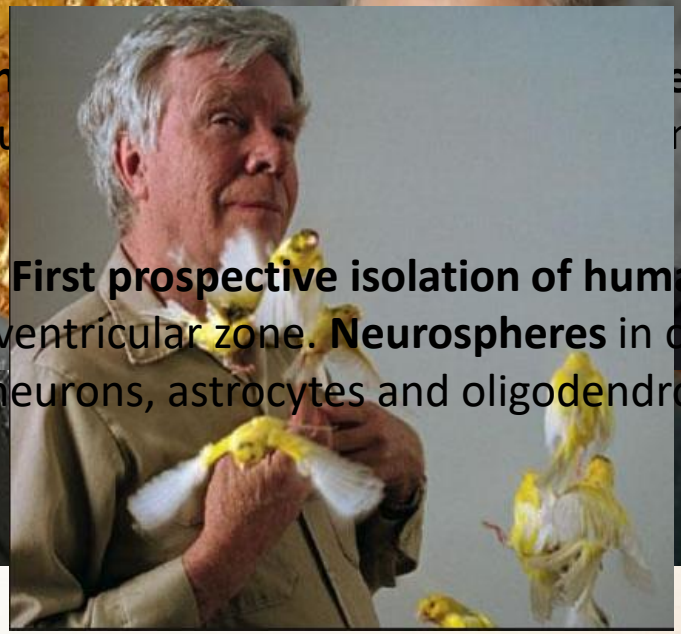

2000 - Nobuko Uchida – First prospective isolation of human CNS stem cells from fetal subventricular zone. **Neurospheres** in culture could differentiate into neurons, astrocytes and oligodendrocytes.

Neural stem cells

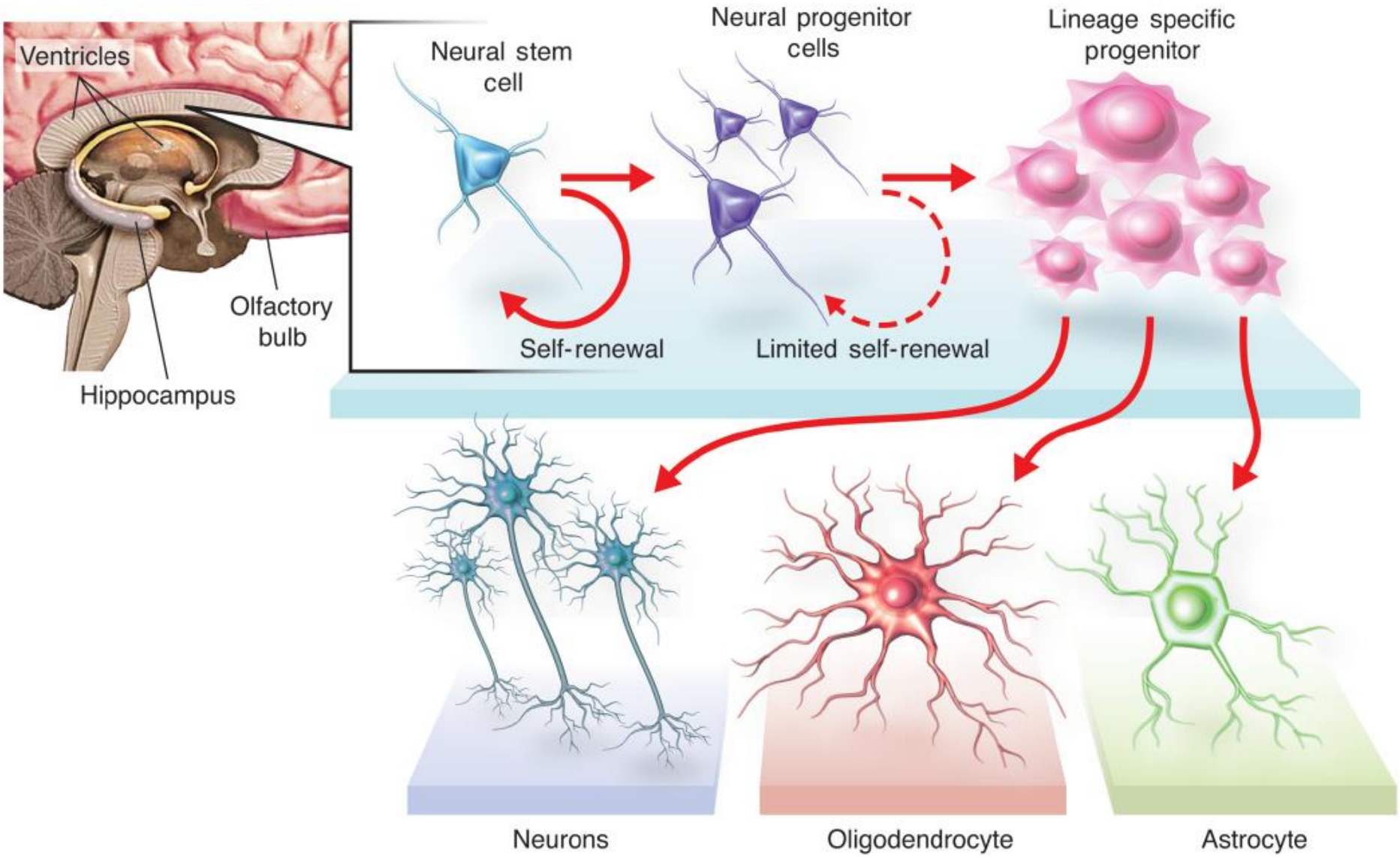

Cheshier SH, Kalani MY, Lim M, Ailles L, Huhn SL, Weissman IL. **A neurosurgeon's guide to stem cells, cancer stem cells, and brain tumor stem cells.** Neurosurgery. 2009 Aug;65(2):237-49.

Neurospheres

- **Cells removed from neurospheres and transplanted to immunosupressed new-born mice brain could graft, migrate and differentiate**
- **These cells when injected at the site of mice spinal cord injury could meliorate motor performance**

Tanaki S, Eckert K, He D, Sutton R, Doshe M, Jain G, Tushinski R, Reitsma M, Harris B, Tsukamoto A, Gage F, Weissman I, Uchida N. Engraftment of sorted/ expanded human central nervous system stem cells from fetal brain. J Neurosci Res 69:976-986, 2002.

Cummings BJ, Uchida N, Tamaki SJ, Salazar DL, Hooshmand M, Summers R, Gage FH, Anderson AJ. Human neural stem cells differentiate and promote locomotor recovery in spinal cord-injured mice. Proc Natl Acad Sci USA 102:14069-14074, 2005.

Disadvantages of embryonic stem cells (ESC)

- The application of heterologous ESC graft in animal models demands high levels of corticoids and host immunosupression

- Ethical and political problems related to ESC
- Theratogenesis (10% teratoma)

A.I.Caplan
pioneer in the fields of developmental biology and regenerative medicine
Identification of mesenchymal stem cells (1981)

Professor of Biology and of General Medical Sciences (Oncology) at Case Western Reserve University in Cleveland.

Mesenchymal Stem Cells

. They were first derived from mice bone-marrow Mononuclear cells (Alexander Friedenstein, 1966)

. They were first called CFU-F: colony-forming unit-fibroblasts

Mesenchymal Stem Cells

1985 – Maureen Owen proposed that CFU-F would be responsible to the bone-marrow stroma formation

1991 – Arnold Caplan proposed that adult bone-marrow MSC could have similar regenerative potential to embryonic stem cells

Mesenchymal Stem cells

. They constitute a small population of bone-marrow mononuclear cells: 0,001 a 0,01% das MNC

. MSC can be isolated, cultured and induced to differentiate in multiple lineages

. They can regenerate a large sort of tissues and organs

Cellular Therapy
Mesenchymal Stem Cells

. MSC are multipotent stem cells capable of self-renewal with the ability to differentiate in: osteoblasts, chondrocytes, adipocytes, and others stromal lineages.

. After scientific intense efforts, and based at the immunomodulatory properties of these cells, they could be differentiated to treat immunologic disorders and degenerative diseases

PLoS Pathog., 2012; 7(8): e43523

Bone-marrow collection

Thomas needle

Collection
Storage
Washing

Bone-marrow filtering

MSC isolation

Bone-marrow aspirate prepared
to cell sorting

MSC isolation

Dilution with culture medium
(DMEM + SFB)

MSC Isolation

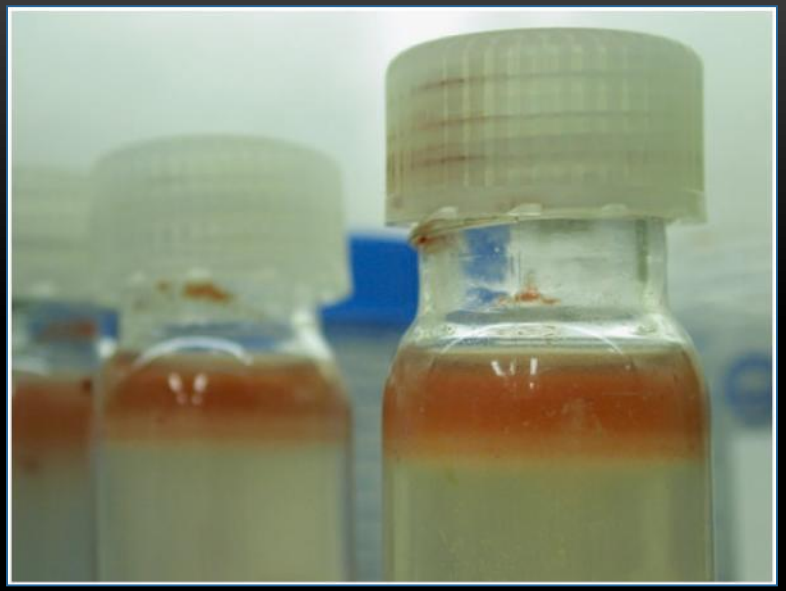

After centrifugation, a layer of MNC is seen at the top of reservoir

Cell culture

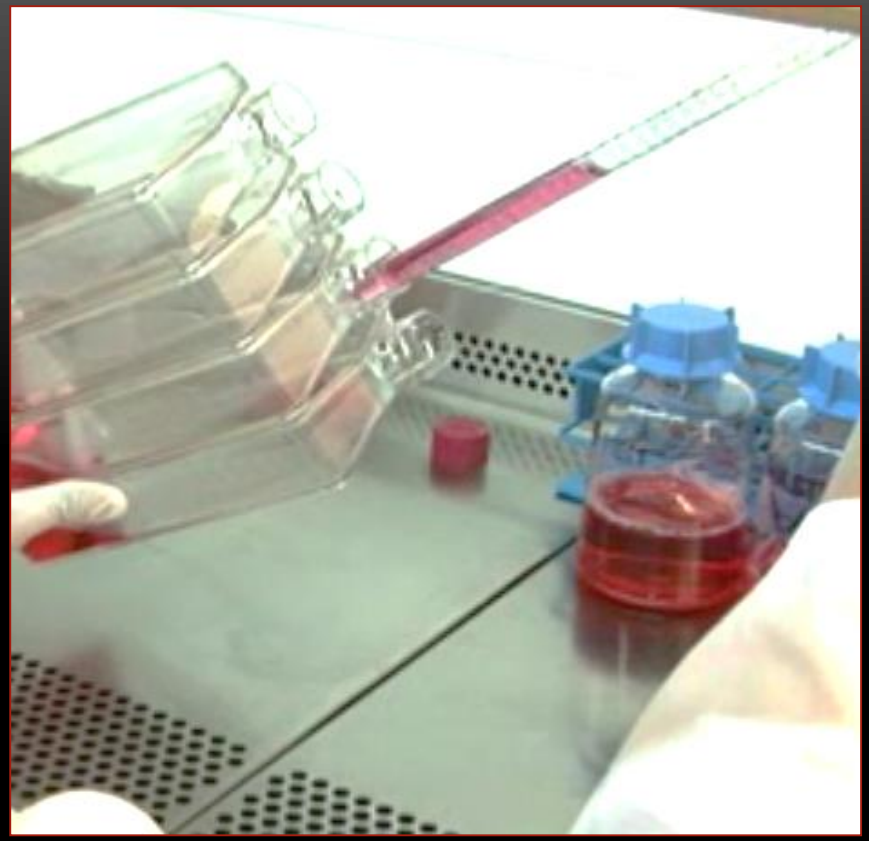

Reservoir with culture medium

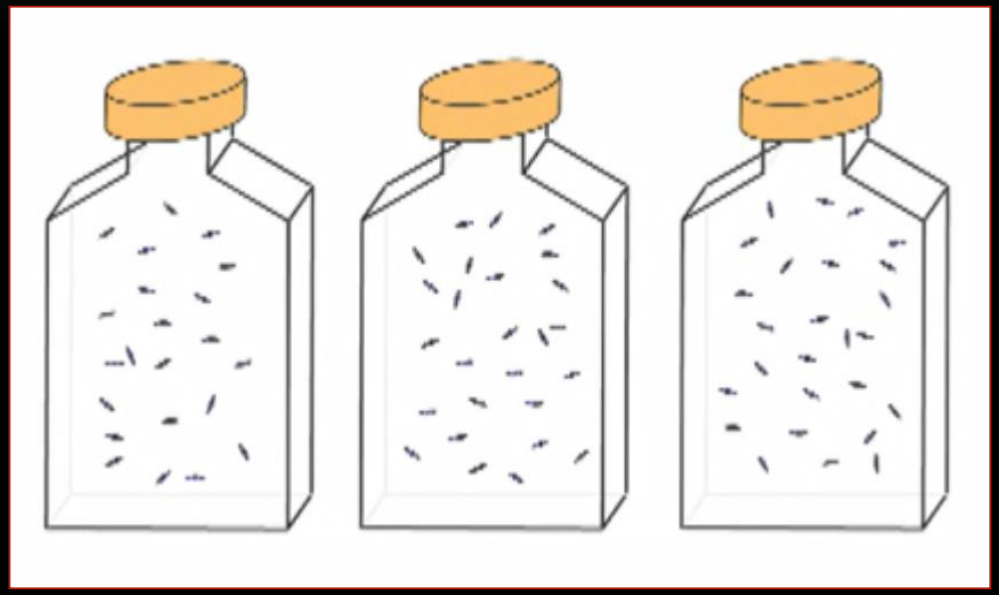

MSC – 7 days

MSC – 11 days

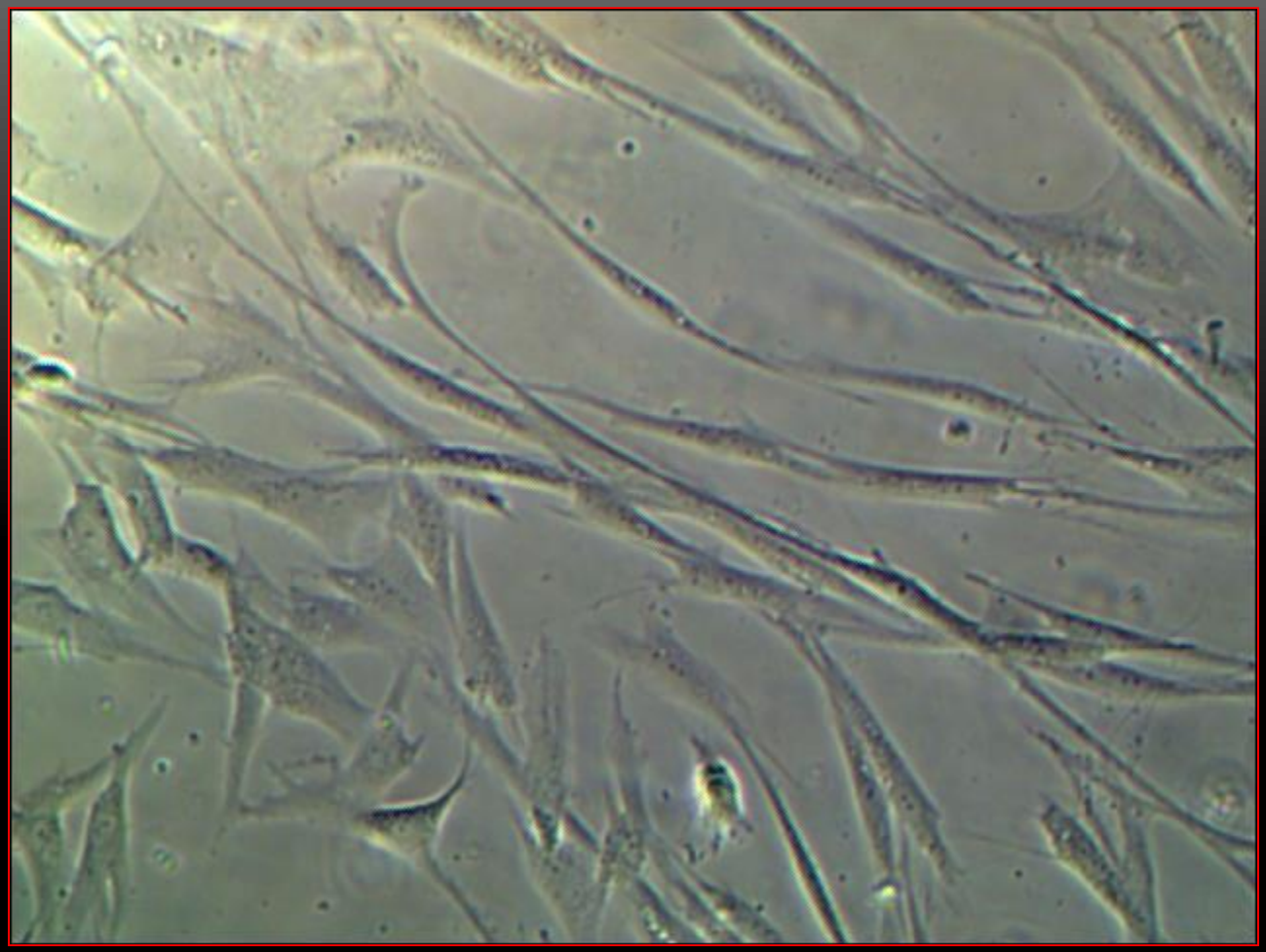

MSC – 15 days

. After an average time of 4 weeks, the population of MSC is prepared to application

. At the day of application: MSC are removed through "tryple" action, washed 2x com PBS e 1x com saline. 1ª application: 8,0 x 10^6 cells em 1 ml of saline.

· MSC acceptable to clinical use: up to 90% cell viability, absence of microbial contamination, CD73 e CD105 expression superior to 90% of the cells

Spine trauma overview

- Brasil: 6-8.000 new cases/ year,

  80% male, 60% 10-30 y
- Inflammatory cascade

  1-2 days: granulocyte infiltration

  5-7 days: macrophage infiltration, phagocytosis of myelin debris and trophic factors to NSC

  3 weeks: trophic factors activates reactional astrocytosis (NOGO, MAM, OMG) and promotes glial scar

Bambakidis NC, Butler J, Horn EM, Wang X, Preul MC, Theodore N, Spetzler RF, Sonntag VKH. Stem cell biology and its therapeutic applications in the setting of spinal cord injury. Neurosurg. Focus 24:E19, 2008.

Prospective clinical essay - MSC spinal cord injury

- Park JH et al.
  - 10 patients with traumatic cervical incomplete spinal cord lesions (ASIA B)
  - Syringomielic cavity at the level of injury
  - Open-intraspinal cord injection of 1 ml = $8x10^6$ MSC and 5 ml = $4x10^7$ MSC intradural, before dural closure
  - 4 and 8 week: lumbar puncture with 8 ml= $5x10^7$

  - Results: 6/10 ameliorates motor performance
  - 3/10 radiological and electrophysiological recovery

Park JH, Kim DY, Sung IY, Choi GH, Jeon MH, Kim KK, Jeon SR. Long-term results of spinal cord injury therapy using mesenchymal stem cells derived from bone marrow in humans. Neurosurgery 70(5):1238-47, 2012.

Prospective clinical essay - MSC spinal cord injury

- Park JH et al.

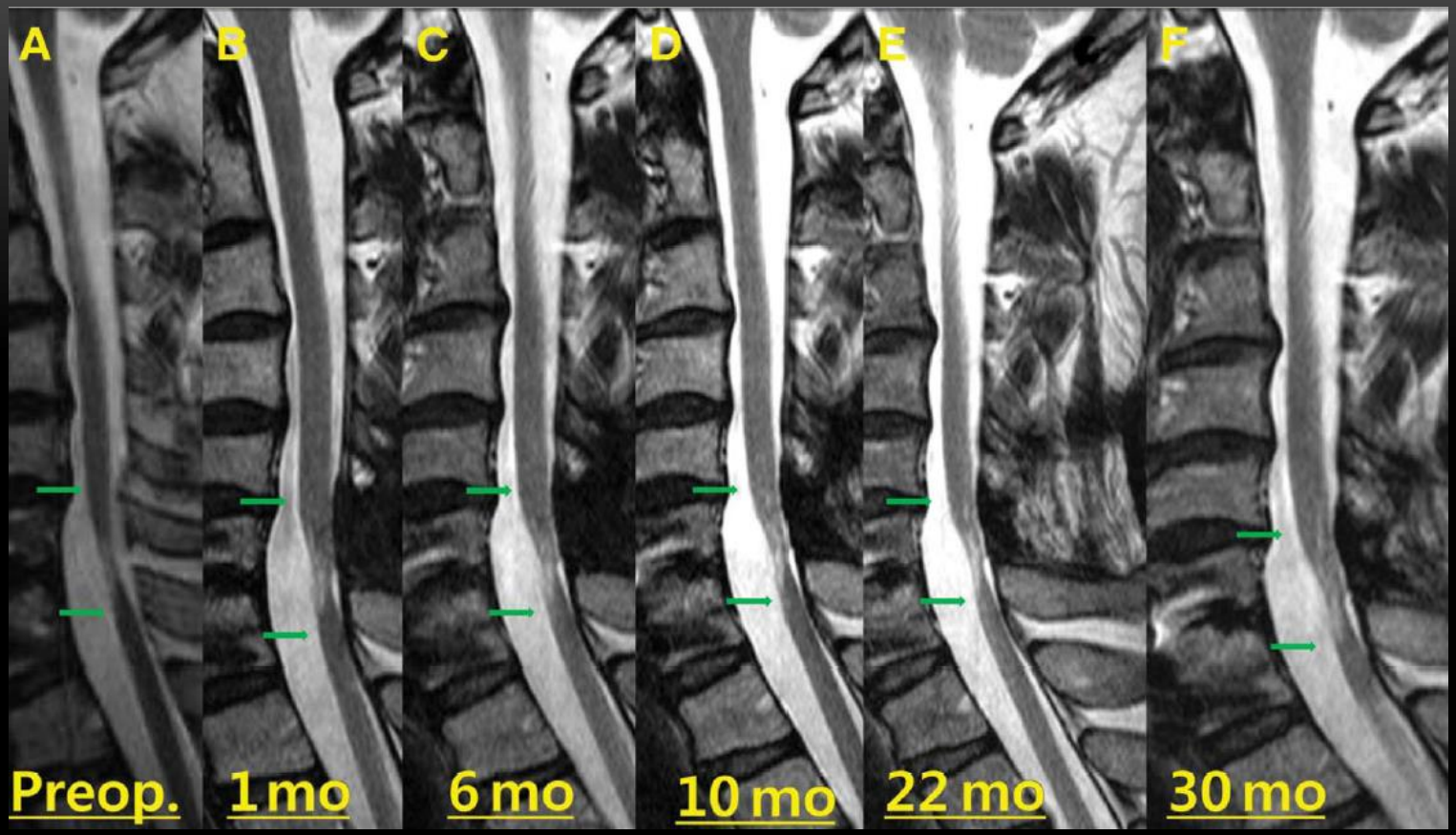

Park JH, Kim DY, Sung IY, Choi GH, Jeon MH, Kim KK, Jeon SR. Long-term results of spinal cord injury therapy using mesenchymal stem cells derived from bone marrow in humans. Neurosurgery 70(5):1238-47, 2012.

???

- Would this MSC protocol function in Clinically Complete Spinal Cord Injury patients, but electrophysiologically incomplete?

- DISCOMPLETE SPINAL CORD LESION???? ***

  (absence of all voluntary motor function below the level of the lesion, but with demonstrable neurophysiological evidence of residual conscious-volitional influence upon spinal reflex activity below the level of injury)

*** Milan Dimitrijevic, Byron Kakulas, Keith Tansey, 1992

EDITED BY

MILAN R. DIMITRIJEVIC, BYRON A. KAKULAS,

W. BARRY McKAY, and GERTA VRBOVÁ

Restorative Neurology of Spinal Cord Injury

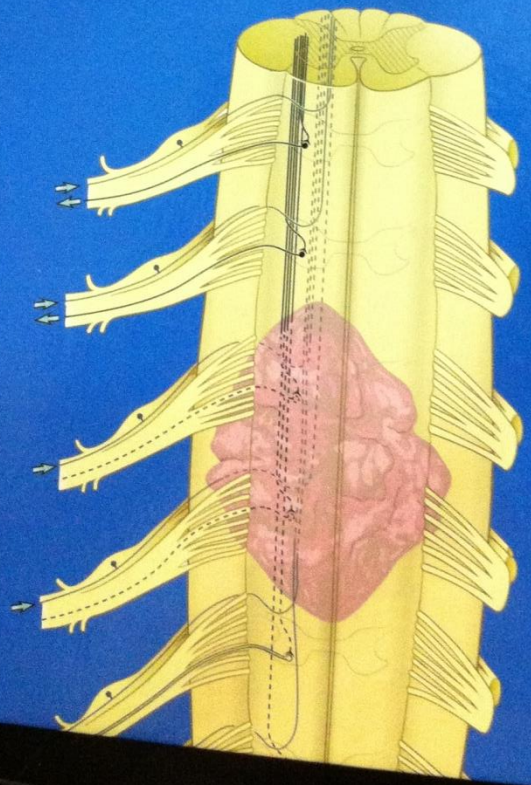

OXFORD

Pilot study

- A 47 year-old Caucasian man presented suddenly an intense low back pain with right leg pain, followed short after by anesthetic paraplegia. Ten hours later he was brought to our hospital.
- On neurological examination there was a flaccid paraplegia with dense sensitive level T4; spinal MRI revealed a large spinal subarachnoid hemorrhage from C7 to S1, with spinal cord compression and myelomalacia from D4 to D6. Further examination showed a tethered cord, with lower conus medullaris at L4, and a sacral SAVM at S1-S2 level.

- **Intervention:** Patient was promptly submitted to a T4-T6 laminectomy with durotomy and hemorrhage drainage, followed a day after by SAVM successfully embolization. Despite our efforts patient remained with anaesthetic paraplegia.

MRI and angio

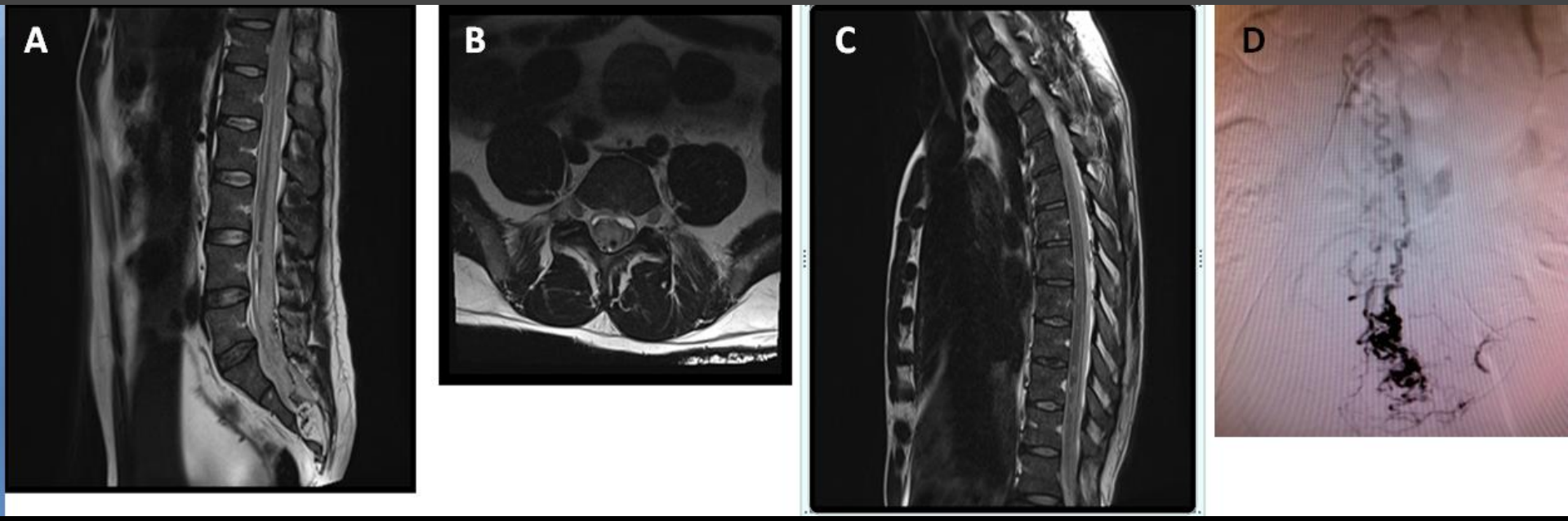

MRI - 2 years

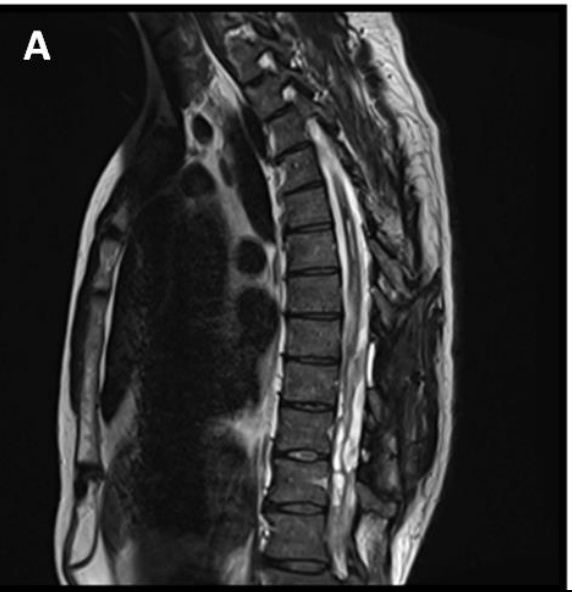

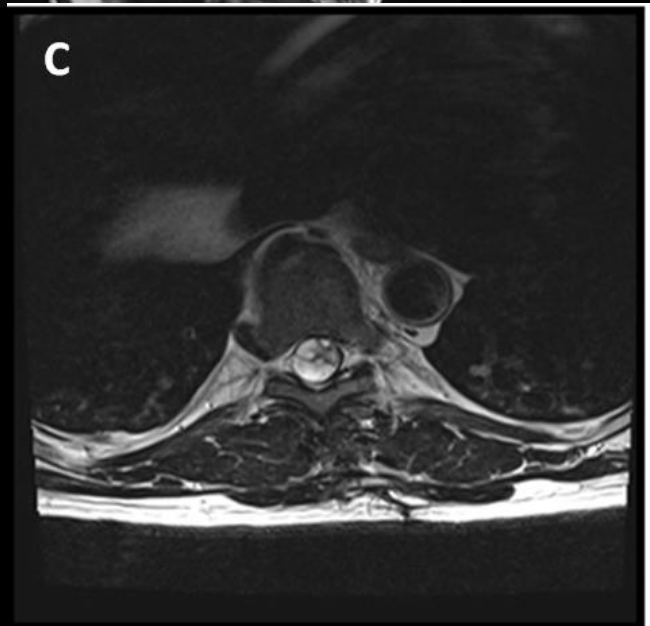

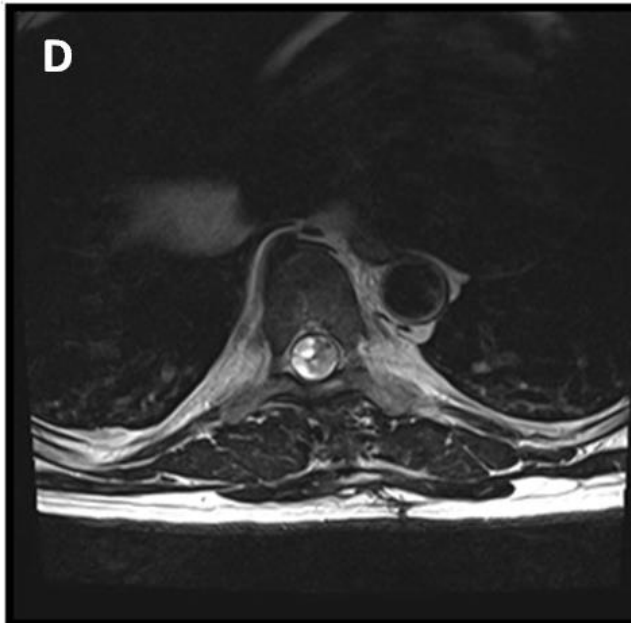

Electrophysiological screening

- Testing suprasegmental influences by surface polyelectromyography below the injury level
  - Patient performs the Jendrassik reinforcement maneuver
  - Performs neck flexion

- Despite ASIA A, patients with suprasegmental influences (residual electrophysiologial activities) may benefit with MSC application

Park et al. MSC protocol

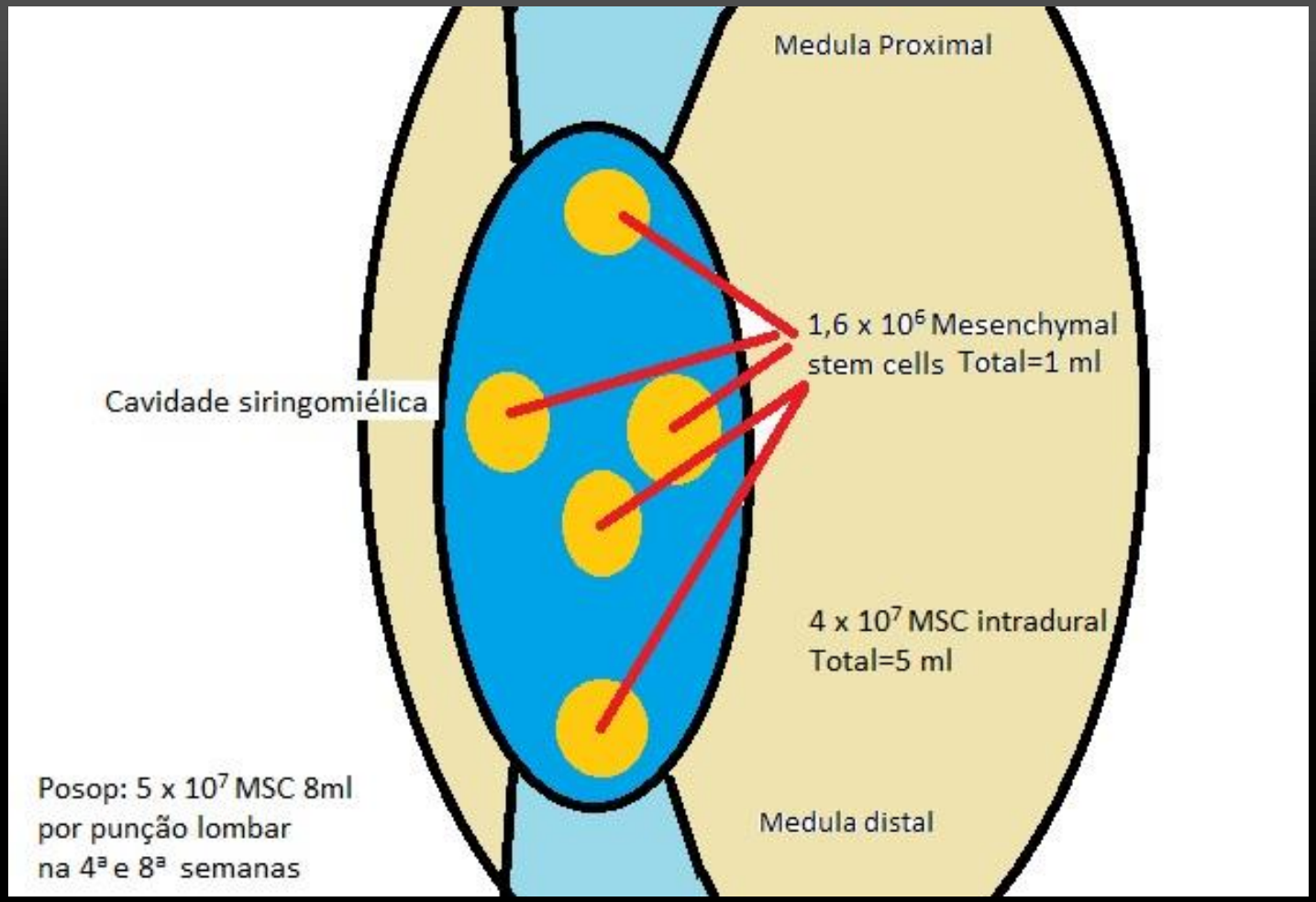

Results after 6 m follow-up (right leg – 400V)

Pre-MSC treatment

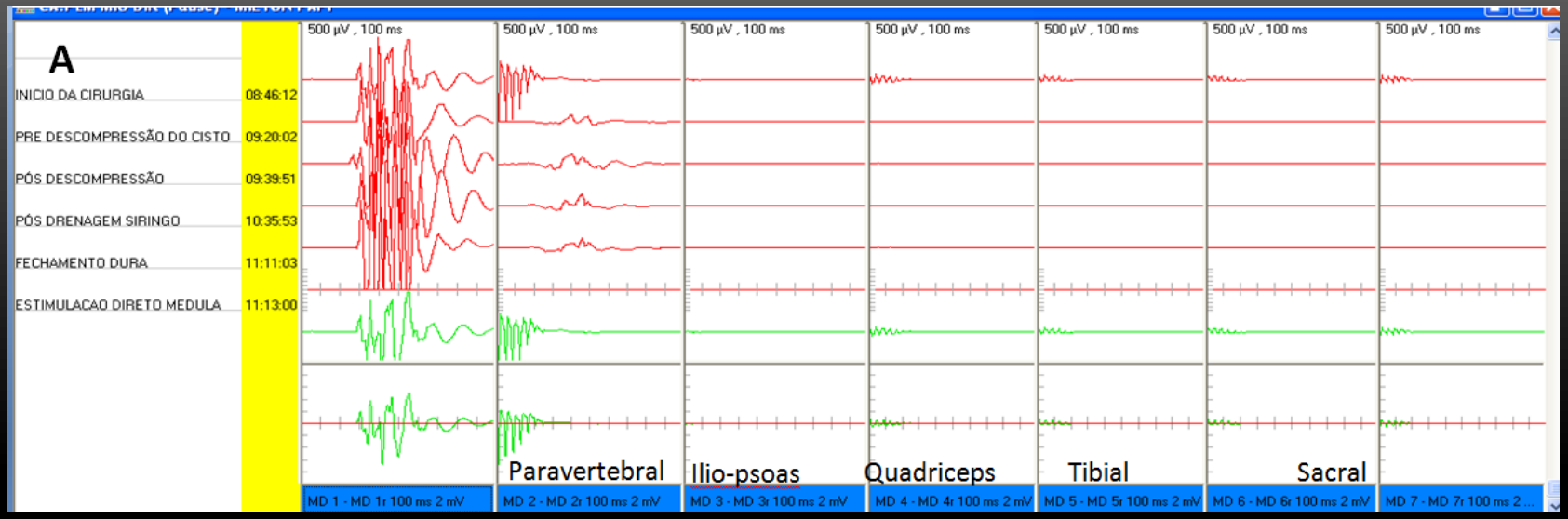

Post-MSC treatment

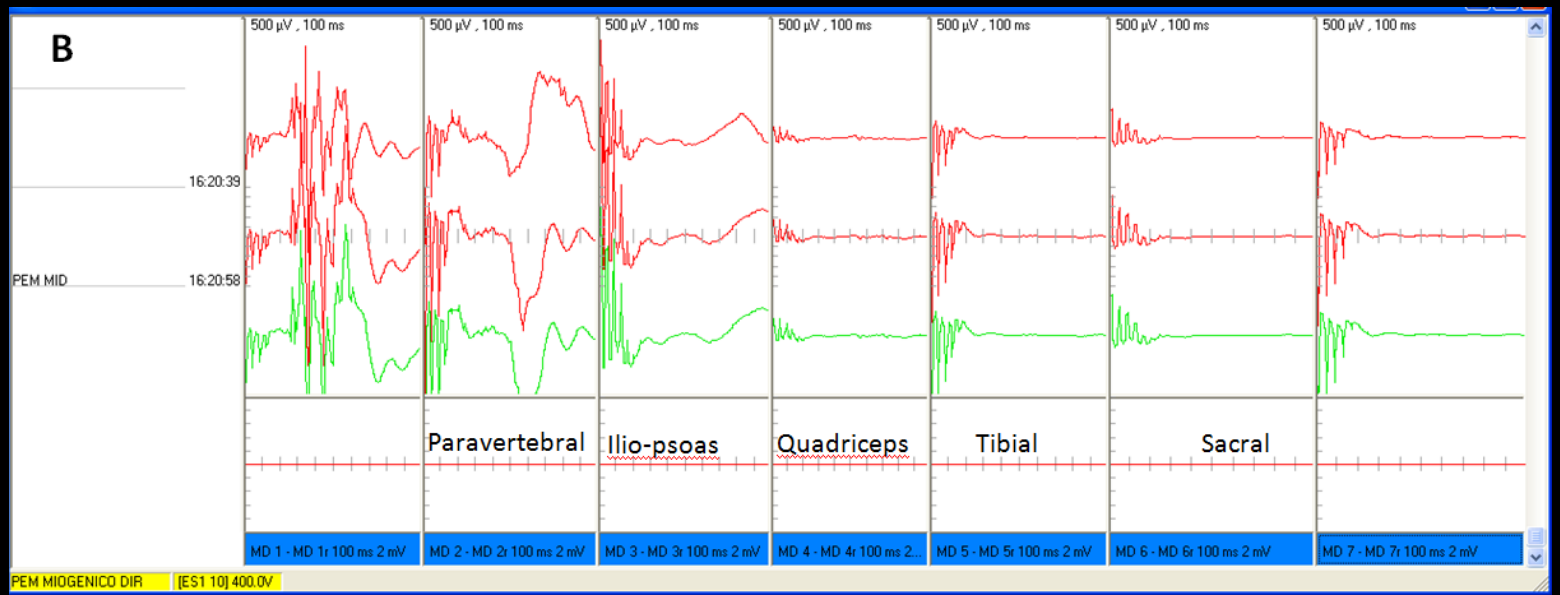

Results after 6 m follow-up (left leg – 400V)

Pre-MSC treatment

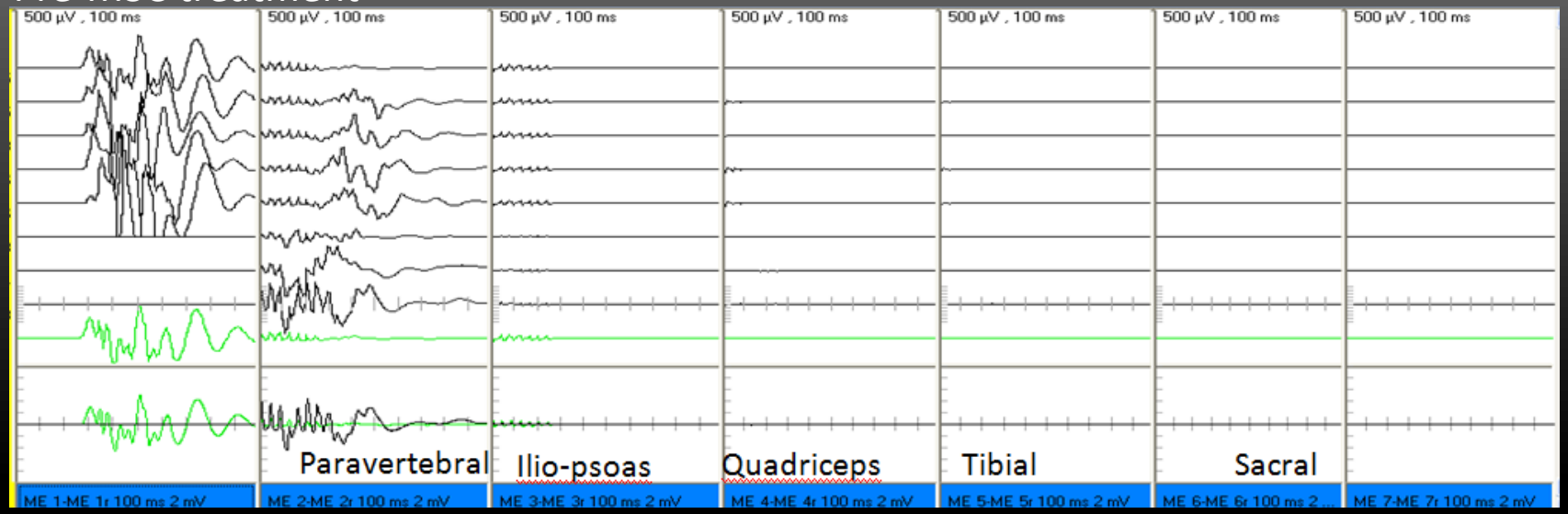

Post-MSC treatment

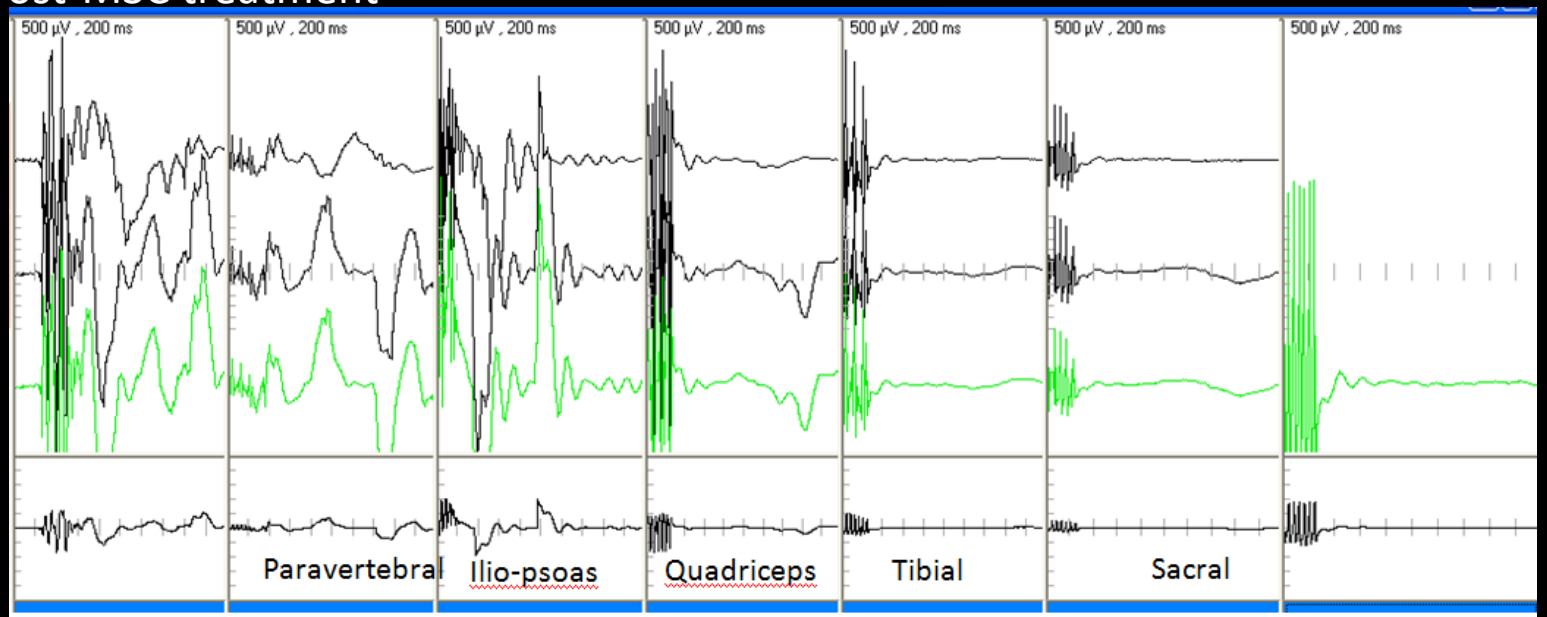

Results after 1 year follow-up (right leg – 400V)

Pre-MSC treatment

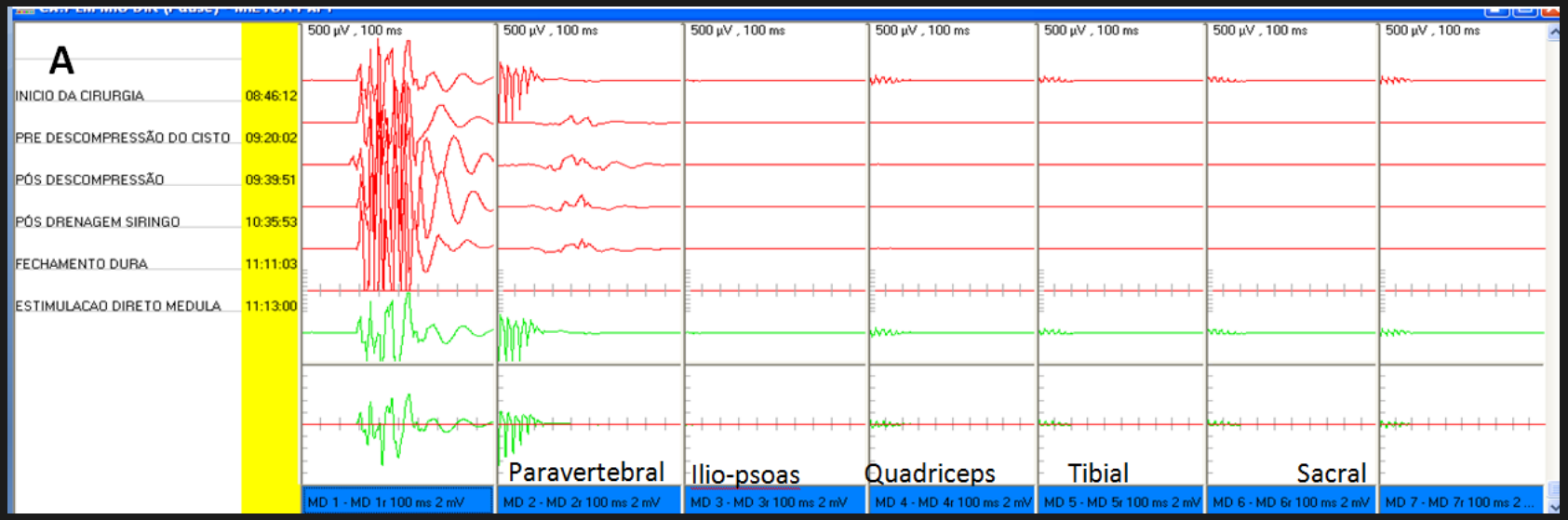

Post-MSC treatment

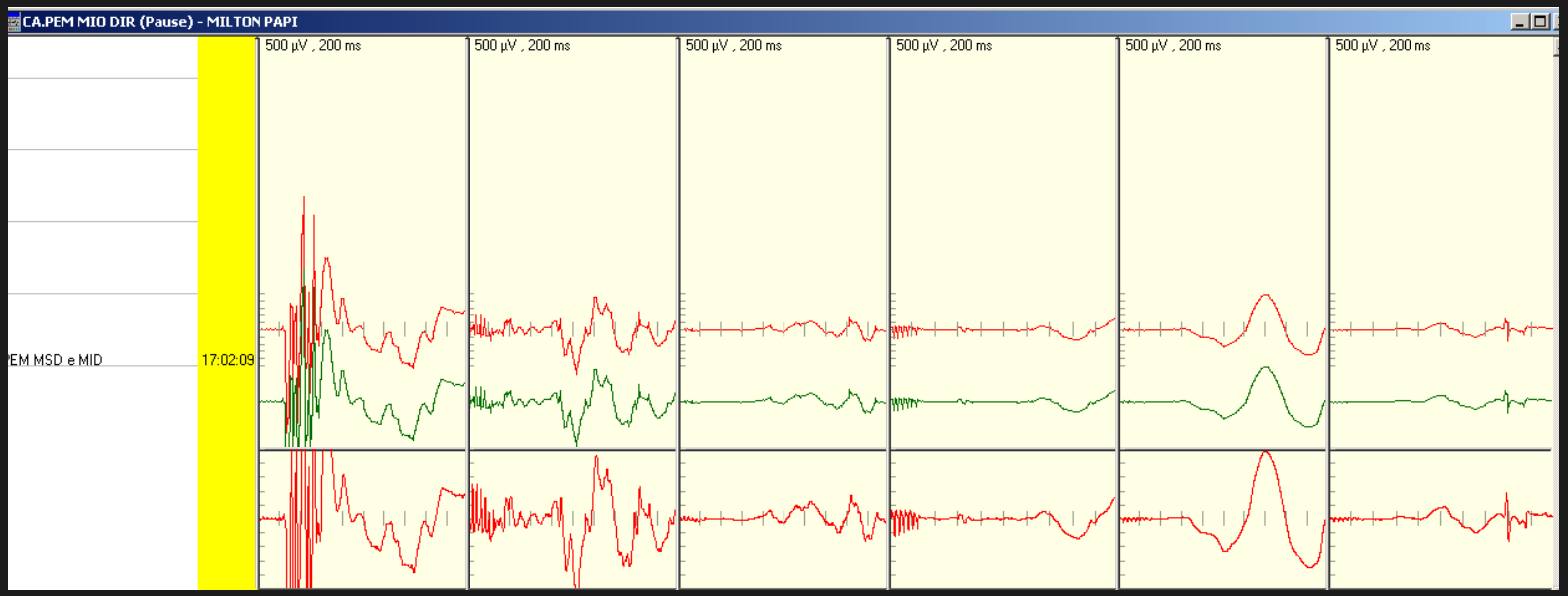

Results after 1 year follow-up (left leg – 400V)

Pre-MSC treatment

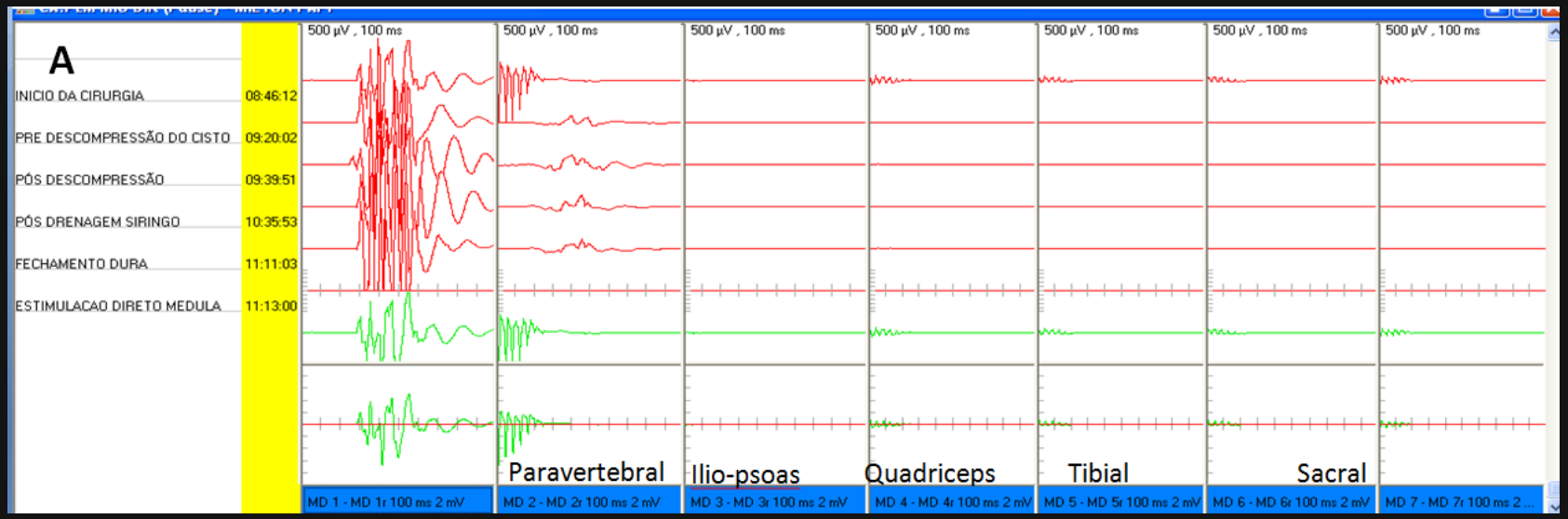

Post-MSC treatment

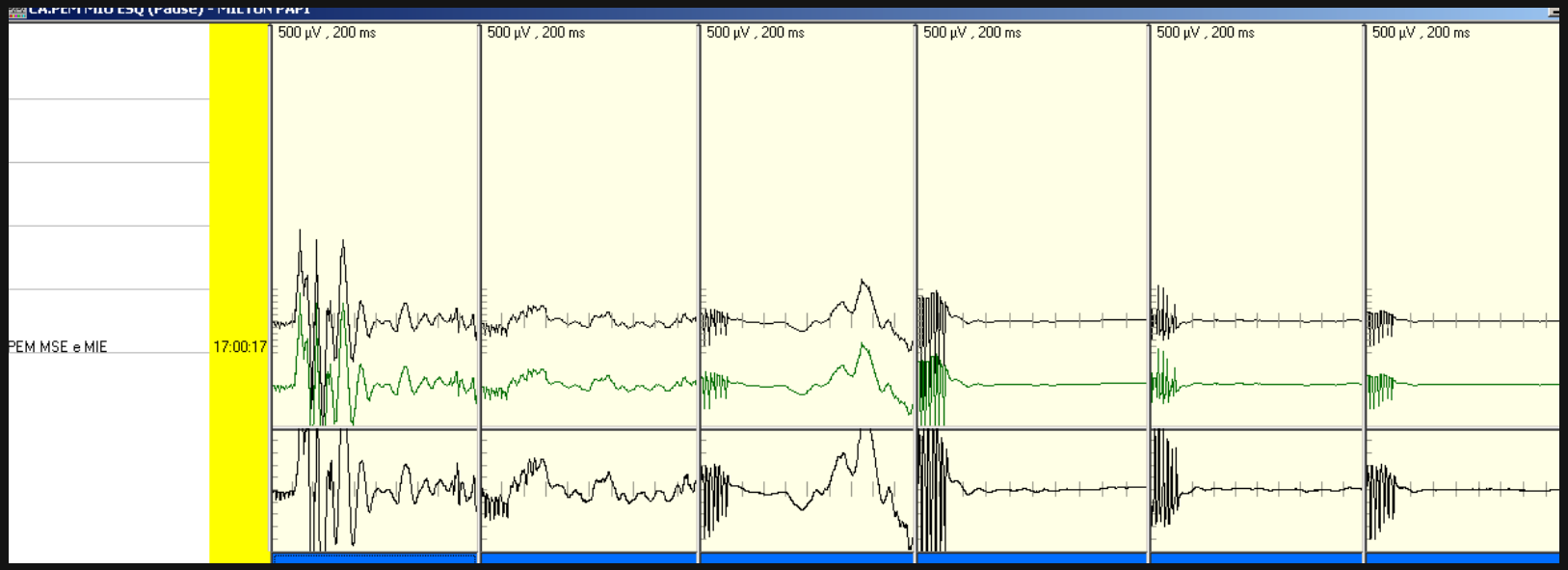

Resultado Funcional (I)



Resultado Funcional (II)

Resultado Funcional (III)

Resultado Funcional - FES (IV)

Arigato gozaimasu!!!
Obrigado!!